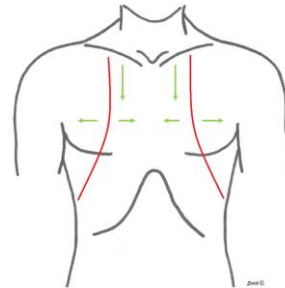
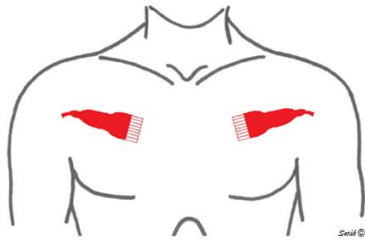




Ultrasound of PNEUMOTHORAX



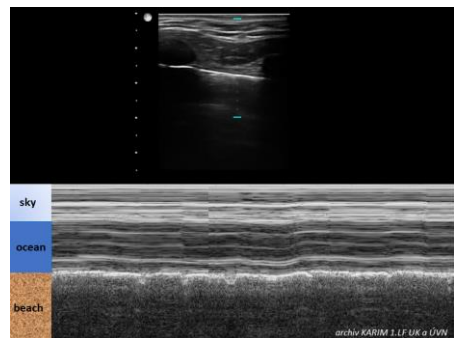
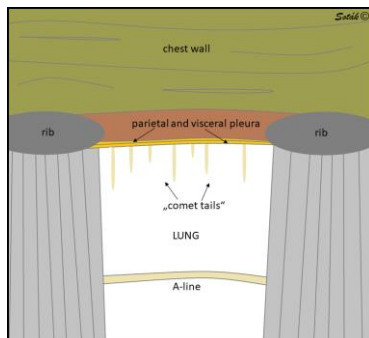
Normal Findings

B-mode:

A-lines
„Lung sliding“
„Comet tails“

M-mode:

„Seashore sign“



Pneumothorax

B-mode:

A-lines
Absence of „Lung sliding“
Absence of „Comet tails“
„Lung point“

M-mode:

„Barcode sign“

